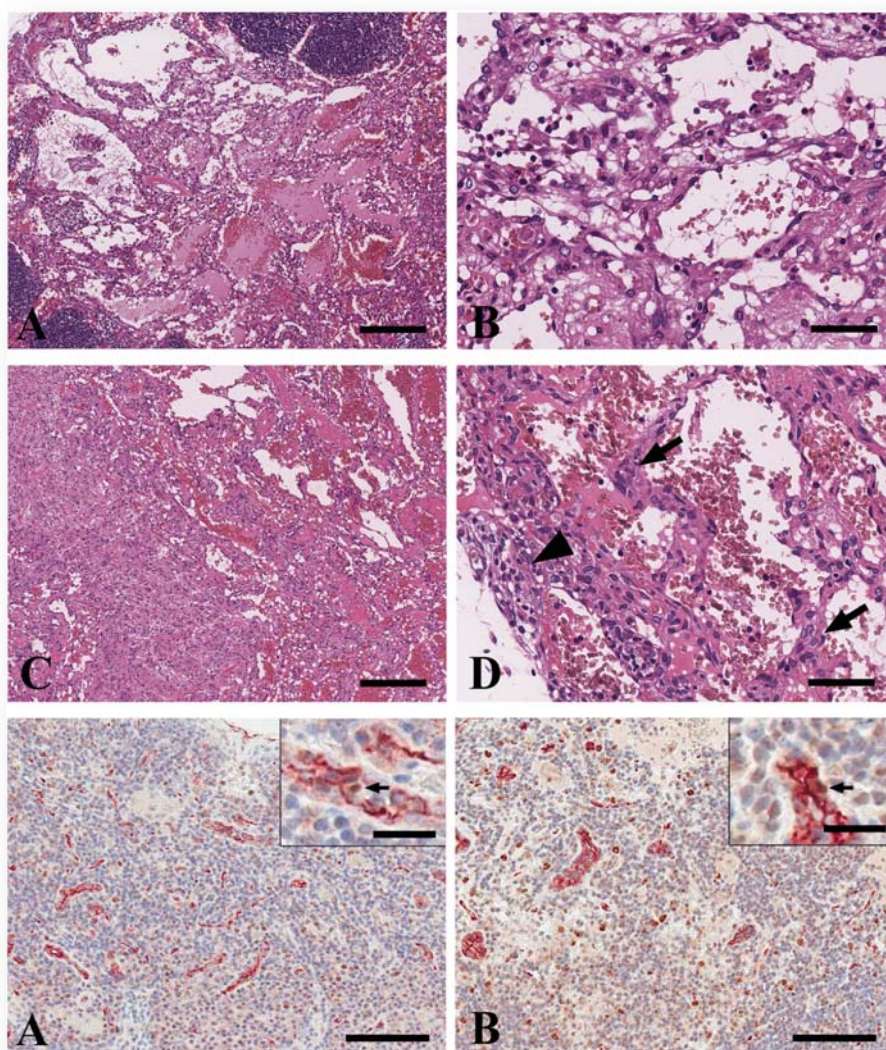




Journal of
**TOXICOLOGIC
PATHOLOGY**

<http://www.japantopath.org/en/publication/jtp/>



*Vol. 29
No. 2
Spring
2016*

**Published by
The Japanese Society of Toxicologic Pathology**

The Journal of Toxicologic Pathology has been selected for coverage in Thomson Reuters products and services. Beginning with volume 21, number 1, year 2008, the journal is indexed and abstracted in:

- ◆ Science Citation Index Expanded (also known as SciSearch®)
- ◆ Journal Citation Reports/Science Edition
- ◆ Biological Abstracts
- ◆ BIOSIS Previews

Description

The *Journal of Toxicologic Pathology* is an official periodical journal of the Japanese Society of Toxicologic Pathology. The journal accepts original papers, short communications, case reports and review articles. One volume published each year is composed of four numbers. Members of the Society are entitled to receive all publications in exchange for his or her membership fee. All articles published in the *Journal of Toxicologic Pathology* represent the opinion(s) of the author(s) and should not be construed to reflect the opinion of the Society.

The *Journal of Toxicologic Pathology* has been selected for coverage in Thomson Reuters products and services. Beginning with volume 21, number 1, year 2008, the journal is indexed and abstracted in:

- ◆ Science Citation Index Expanded (also known as SciSearch[®])
- ◆ Journal Citation Reports/Science Edition
- ◆ Biological Abstracts
- ◆ BIOSIS Previews

Mailing address: Masami Suzuki, D.V.M., Ph.D., Editor-in-Chief
Editorial Office, *Journal of Toxicologic Pathology*, c/o Publication Center, IPEC, Inc., 1-24-12 Sugamo, Toshima,
Tokyo 170-0002, Japan

Journal of Toxicologic Pathology homepage: <http://www.japantoxpath.org/en/publication/jtp/>

Free access to full papers of

Whole issue: <https://www.jstage.jst.go.jp/browse/tox/>

Vol. 22 (2009) to present: <http://www.ncbi.nlm.nih.gov/pmc/journals/1592/>

Notice for photocopying

If you wish to photocopy any work of this publication, you have to get permission from the following organization to which licensing of copyright clearance is delegated by the copyright owner.

<All users except those in USA> Japan Academic Association for Copyright Clearance, Inc. (JAACC)
6-41 Akasaka 9-chome, Minato-ku, Tokyo 107-0052, Japan
Phone 81-3-3475-5618 FAX 81-3-3475-5619 E-mail: info@jaacc.jp

<Users in USA> Copyright Clearance Center, Inc., 222 Rosewood Drive, Danvers, MA 01923, USA
Phone 1-978-750-8400 FAX 1-978-646-8600

Online ISSN 1881-915X

Cover: Upper: Histopathological findings of hemangiomas (A, B) and hemangiosarcomas (C, D) of the mesenteric lymph node in male SD rats in a 2-year carcinogenicity study. Hemangioma was characterized by a nonencapsulated proliferation of a single layer of uniform endothelial cells without pronounced pleomorphism or atypia. Mitoses were seldom seen. B shows a higher magnification of A. Hemangiosarcoma was characterized by moderate pleomorphism to atypia of the lining endothelium, which was multilayered and solid (arrows). Undifferentiated areas of sarcomatous tissue or local invasion were sometimes visible (arrowhead). D shows a higher magnification of C. H&E stain. Bar = 200 μ m (A, C) or 50 μ m (B, D).
Lower: Double immunostaining for PCNA (brown) and CD34 (red) in nuclei and endothelial cytoplasm, respectively, in mesenteric lymph nodes that did not have a hemangioma or hemangiosarcoma in the control (E) and high-dose (F) groups. No differences were noted. Bar = 100 μ m. The arrows indicate PCNA/CD34 double-positive cells (inset, bar = 20 μ m). (See Minoru Sasaki, *et al.* p 85–93)