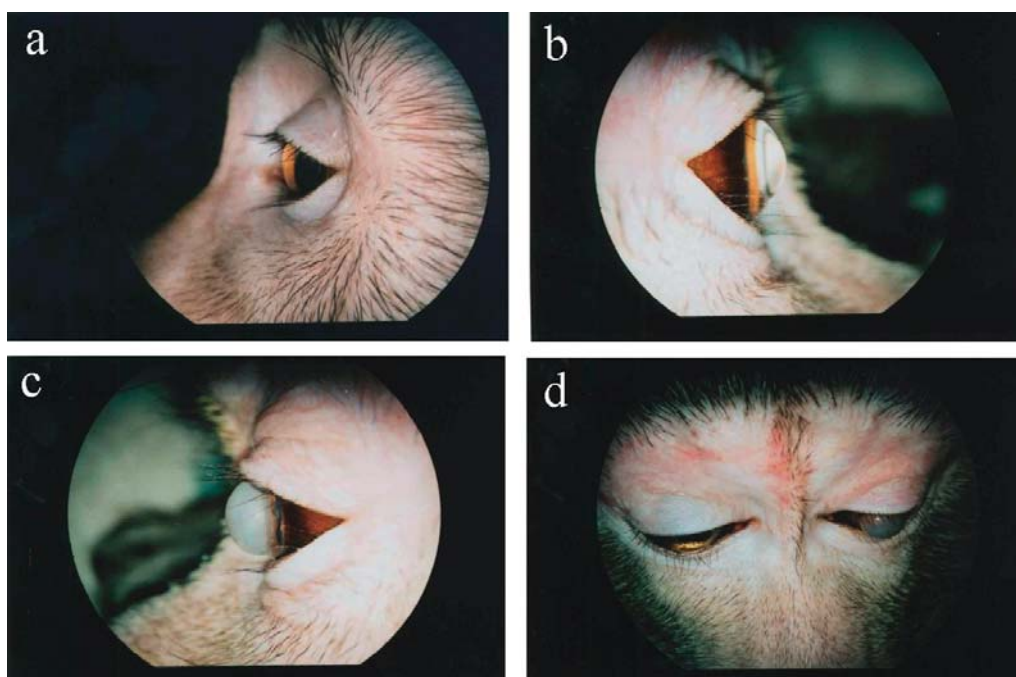




*Journal of*  
**TOXICOLOGIC  
PATHOLOGY**

<http://wwwsoc.nii.ac.jp/jstp3/english/Journal.html>



*Vol. 23  
No. 1  
Spring  
2010*

**Published by**  
**The Japanese Society of Toxicologic Pathology**

*Editor-in-Chief*

Dai Nakae, *Tokyo*

*Editor Emeritus*

Eisei Ishikawa (1988–1997)

*Former Editors-in-Chief*

Kunio Doi (1998–2003)

Kunitoshi Mitsumori (2003–2007)

*Editorial Board (Editors)*

Wijit Banlunara, <i>Bangkok</i>	John Curtis Seely, <i>North Carolina</i>
Satoshi Furukawa, <i>Saitama</i>	Makoto Shibutani, <i>Tokyo</i>
Paul-Georg Germann, <i>Barsbüttel</i>	Kazumoto Shibuya, <i>Tokyo</i>
Katsumi Imaida, <i>Kagawa</i>	Masami Suzuki, <i>Shizuoka</i>
Keisuke Izumi, <i>Tokushima</i>	James Swenberg, <i>North Carolina</i>
Hijiri Iwata, <i>Itingen</i>	Kazutoshi Tamura, <i>Shizuoka</i>
Jong-Koo Kang, <i>Cheongju</i>	Leander Tryphonas, <i>Ontario</i>
Osamu Katsuda, <i>Nara</i>	Tetsuya Tsukamoto, <i>Aichi</i>
Wolfgang Kaufmann, <i>Ludwigshafen</i>	Masahiro Tsutsumi, <i>Nara</i>
Yuji Oishi, <i>Osaka</i>	Klaus Weber, <i>Itingen</i>
Kumiko Ogawa, <i>Tokyo</i>	Midori Yoshida, <i>Tokyo</i>
Jin Ren, <i>Shanghai</i>	Naomi Yoshimi, <i>Okinawa</i>
Hiroshi Satoh, <i>Tokyo</i>	Katsuhiko Yoshizawa, <i>Osaka</i>

*Description*

The *Journal of Toxicologic Pathology* is an official periodical journal of the Japanese Society of Toxicologic Pathology. The Journal accepts original papers, short communications, case reports and review articles. One volume published each year is composed of four numbers. Members of the Society are entitled to receive all publications in exchange for his or her membership fee. All articles published in the Journal of Toxicologic Pathology represent the opinion(s) of the author(s) and should not be construed to reflect the opinion of the Society.

*Mailing address:* Dai Nakae, M.D., Ph.D., Editor-in-Chief  
Editorial Office, Journal of Toxicologic Pathology  
c/o Publication Center, IPEC, Inc.  
1-24-12 Sugamo, Toshima, Tokyo 170-0002, Japan

*Journal of Toxicologic Pathology homepage:* <http://wwwsoc.nii.ac.jp/jstp3/english/Journal.html>

Free access to full papers of

Vols. 1 (1988)–10 (1997): [http://www.journalarchive.jst.go.jp/japanese/jnltop\\_ja.php?cdjournal=tox1988](http://www.journalarchive.jst.go.jp/japanese/jnltop_ja.php?cdjournal=tox1988)

Vol. 11 (1998) or later: <http://www.jstage.jst.go.jp/browse/tox/-char/en>

*Notice for photocopying*

If you wish to photocopy any work of this publication, you have to get permission from the following organization to which licensing of copyright clearance is delegated by the copyright owner.

<All users except those in USA> Japan Academic Association for Copyright Clearance, Inc. (JAACC)  
6-41 Akasaka 9-chome, Minato-ku, Tokyo 107-0052, Japan  
Phone 81-3-3475-5618 FAX 81-3-3475-5619 E-mail: [info@jaacc.jp](mailto:info@jaacc.jp)

<Users in USA> Copyright Clearance Center, Inc., 222 Rosewood Drive, Danvers, MA 01923, USA  
Phone 1-978-750-8400 FAX 1-978-646-8600

Online ISSN 1881-915X

**Cover:** Keratoconus in a Cynomolgus Monkey. a) Macroscopic appearance of the left eye in the normal monkey. b) Macroscopic appearance of the right eye in the present case. The cornea becomes conical and protrudes from the center. c) Macroscopic appearance of the left eye in the present case. Severe edema with opacity covers the corneal surface. d) Macroscopic appearance of the face in the present case. The upper eyelid and forehead have wide-ranging erythema. Both corneas become conical and protrude from the center. Acute edema occurred in the left eye. (See Kodama R, et al. p53–60)